

INTEGUMENTARY SYSTEM

The skin and associated structure make up in the integumentary system. The skin is a mammal's largest organ. It protects the body against physical, chemical and biological attacks, It regulates body temperature, it is used to communicate to other individuals and skin derivatives provides nourishment for the young.

Like the integuments of other vertebrates, mammalian skin is composed of 2 layers, the dermis and epidermis

Figure: Cross-sectional diagram of skin surface (Martin and Neelase 1981)

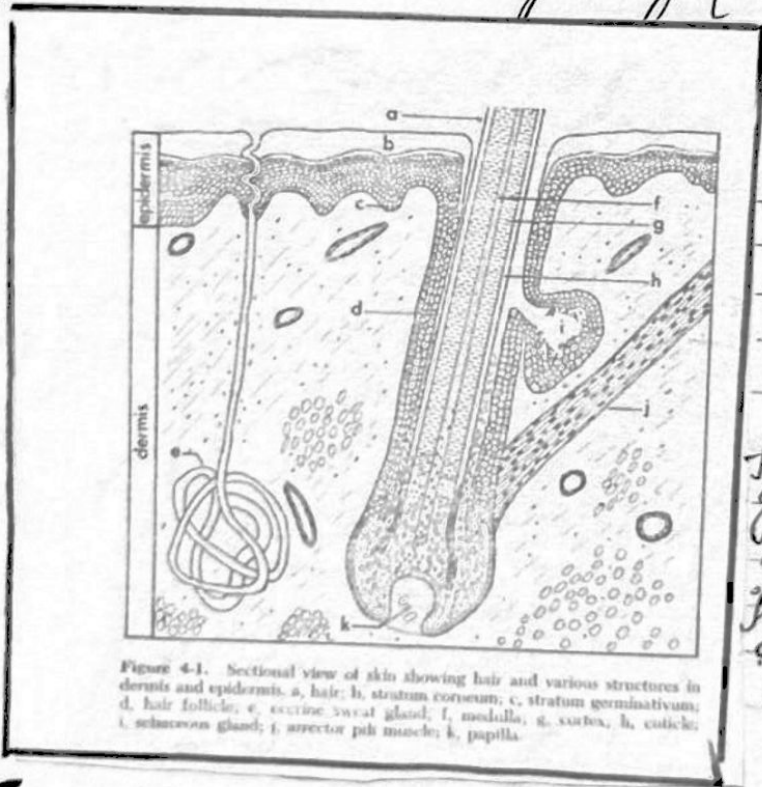


Figure 4-1. Sectional view of skin showing hair and various structures in dermis and epidermis. a, hair; b, stratum corneum; c, stratum germinativum; d, hair follicle; e, eccrine sweat gland; f, medulla; g, cortex; h, cuticle; i, sebaceous gland; j, arrector pili muscle; k, papilla.

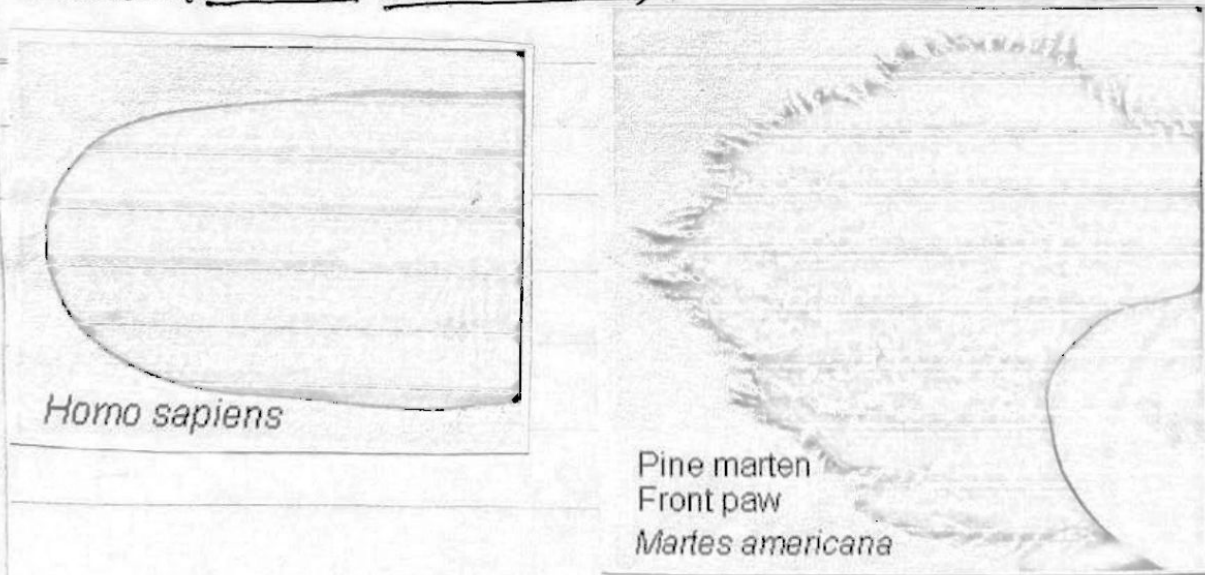
- Fig: a) hairs;
- b) stratum corneum
- c) stratum germinativum
- d) hair follicle
- e) eccrine sweat gland
- f) medulla
- g) cortex @ cuticle
- i) sebaceous gland
- j) arrector pili muscle
- k) papilla.

EPIDERMIS: The epidermis consist of several layers representing successive stages of development. The oldest part of skin is the outer layer of tough

proliferative, cells, The cells which are dead are continually worn off at their surface and replaced from below. As the cells age and mature, they eventually lose their nuclei and most of the cell contents are converted into keratin.


The outermost layer of epidermis is stratum corneum. The epidermis on the scales of feet and the palms of hands is thick. Elsewhere on the body, the epidermis may be quite thin. Thickened portions of epidermis form the pads on the feet of most mammals and friction ridges on the digits and palms of primates. Finger prints are the impressions of these friction ridges.

Figure: Fingerprint of human (Homo sapiens). We may have an opportunistic sample of (e.g. last year had a pine marten (Martes americana)).

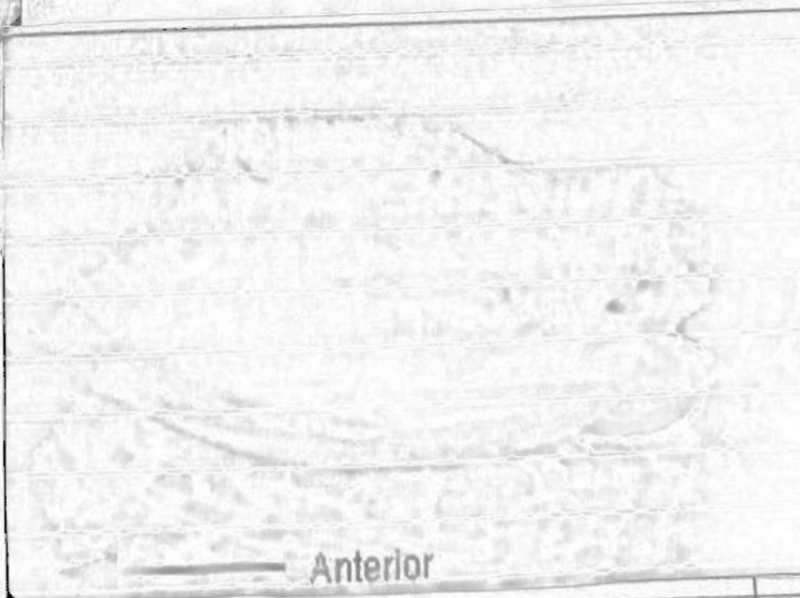


DERMIS: The dermis lies below the epidermis. It is a thick layer of connective tissue with associated muscle, nerve & blood vessels. The connective tissue consist largely collagen. collagen may be upto 6% of body weight in humans and most abundant protein, being present in skin, bone, tendons & ligaments. collagen is from a Greek word mean 'glue-maker'. collagen and other fibers in dermis become toughened during process of tanning when skin transformed into leather. dermis is well supplied with blood vessels & nerve for sensation, touch temperature & pain.

Fig: Subcutaneous fat in deer in winter. This picture is of the subcutaneous fat of yearling deer that was hit by car on 12/04 on the left image from just anterior to the tail cut through the tissue and on the right is one of back with tissue and on the right one of the back with skin puffed back.



Odocoileus virginianus Back fat



Anterior

SKIN GLAND: Associated with the skin are two kind of gland sweat gland & sebaceous glands. The epidermal sebaceous gland lubricates the hair and are described below. Sweat gland are coiled tubular in the dermis connected with the surface by narrow ducts. They are well developed with blood vessels, secrete mostly water & salt and function largely thermoregulation. Mammary gland evolved from sweat glands are discussed below

Hairs

General: Hair is a uniquely mammalian feature. The developing epidermis invaginates into the dermis to a form follicle. At the deepest point of invagination, the dermis pushes back and forms a small structure called papilla. The papilla is well supplied with blood vessels.

Each hair consist of three parts. The inner medulla this is surrounded by a denser cortex & give each hair its characteristic colour. The cortex covered by thin layer called cuticle. Cuticular scales are often characteristics of particular genera or even species of mammals. They are never pigmented.

Glands: Sebaceous glands open into each follicle. They secrete oily substances that continually lubricate and condition skin and hair cells inside glands gradually fill with grease.

There are many examples of skin gland that have evolved beyond their roles in lubrication to skin therefore we have a skin study with laboratory but don't have and see

Figure: Scent gland in the white-tailed deer (*Odocoileus virginianus*) lips from a deer may be available in class to find these glands.

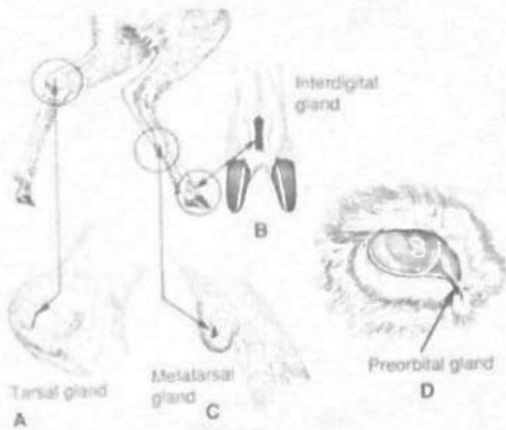
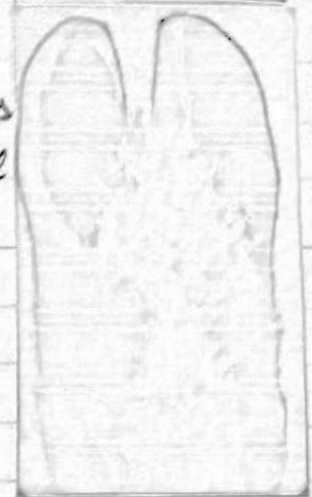

Fig:- Scent glands in white tailed deer, *Odocoileus virginianus*. A. Tarsal gland; B. interdigital gland; C. metatarsal gland; D: preorbital gland.



Hair musculature :-

Hairs does not grows vertically from the skin but Emerges at an angle, which can be altered to regulate the depth of the pelage. A small arrector pili (plural, arrectores pilorum) muscle is attached to each follicle. As the muscle contracts, it increases the thickness of the insulating layer of hair.

Kinds of hairs :- Hairs with continuous growth (human head / hair on a horse mane) is called angora hair. It contracts to grow throughout the life of the animal and not molts.

The pelage (or coat) that we usually see in body hairs or guard hair. There are three different types of guard hairs. Guard hairs are frequently long stiff hairs. Some are guard hairs with definite growth and are most noticeable hairs on mammals.





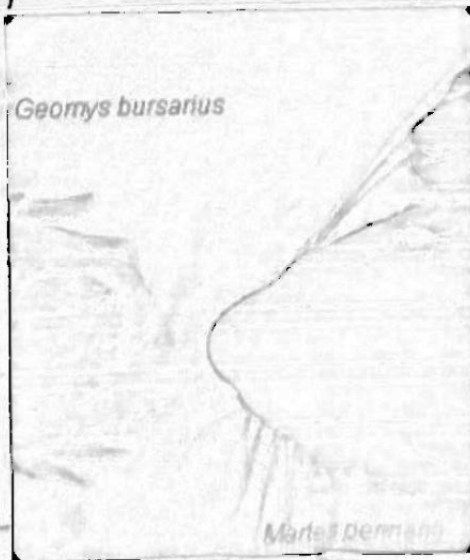
Fig: Enlarged view of a quill tip of a New world porcupine (*Echthyrion dorsatum*) - note presence of barbs.



Underhairs are shorter and finer hairs growing around the guard hairs often in much greater numbers. Their function is to insulate. Underhairs with angora growth are called wool. In domestic sheep, guard hairs have been eliminated through selective breeding and the growth rate & density of the wool has been increased.

The pelage of an animal is the combination of longer guard hairs and the underfur (underline) fine and relatively short hair with definitive growth that densely covers most mammals. Special tactile hairs, the vibrissae, are found not only on a mammal's face (mystacial vibrissae) but may occur also on the legs or elsewhere on the body.

Figure: vibrissae on the porcupine & the pocket gopher (*Geomys bursarius*)




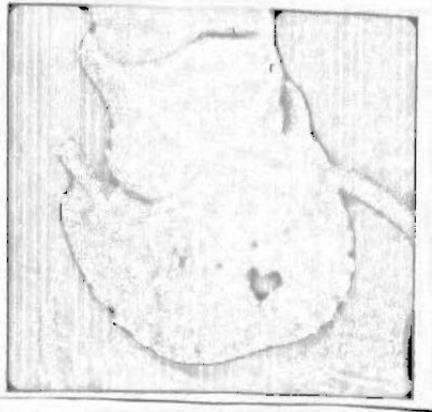


Colour :- Mammalian hair and skin colouration serves three basic functions: 1) protection from electric magnetic radiation (especially ultraviolet light) 2) Concealment (crypsis) by camouflage, counter shading and 3) communication such as the "warning" colour pattern in skunks (*Mephitis mephitis*)

Bright colours are rarely found in mammals are nocturnal and most are colour blind. Primates are exceptions; they have colour vision and many display brightly coloured patches and brilliantly pigmented areas of bare skin.

The colour of an individual hair mainly depends on the kind and concentration of pigment granules in the cortex, surface textures, the thickness of the hair, and the amount of air space in the medulla also influence its appearance. Most hairs show a pattern called agouti; they have a dark tip followed by successive bands of different pigments.

Hair replacement: The pelage must be maintained its functionality. Hair cannot be repaired when it is damaged because of it is nonliving. Two kinds of molts are recognized: maturational molt (from juvenile to sub-adult pelage); and seasonal molt which usually occurs once or twice a year and often follows a regular seasonal pattern within a particular species. Some mammalian species have white coats for winter and darker coat for summer.



The following specimens are available in the lab today
 other species will be available in next lab.

<u>Order</u>	<u>Family</u>	<u>Specimen</u>	common name.
Artiodactyla	Cervidae	<u>Odocoileus virginianus</u>	white-tailed deer
Carnivora	Mephitidae	<u>Mephitis mephitis</u>	striped skunk
Rodentia	Erthizontidae	<u>Ethiopsis dorsatum</u>	porcupine
Rodentia	Creamyidae	<u>Creamys brevicaudus</u>	pocket gopher
Artiodactyla			
Rodentia	Castoridae	<u>Castor canadensis</u>	Beaver
Artiodactyla	Cervidae	<u>Cervus elaphus</u>	Elk
Artiodactyla	Cervidae	<u>Alces alces</u>	Moose
Artiodactyla	Cervidae	<u>Odocoileus virginianus</u>	white-tailed deer.

Hooves: - Well developed hooves are found among extant mammals only in ungulates (Artiodactyla and Perissodactyla). They are further modified claw in which the unguis encloses both end of the digits and the sub-unguis. The softer subunguis wears away more quickly than the unguis thus forming a sharp edge. The protuberance just behind the hoof and is called the frog.

Figure: pictures of *Bos taurus* hoof in laboratory

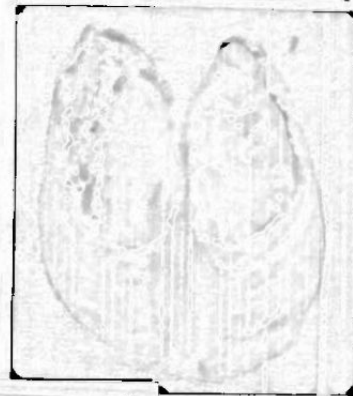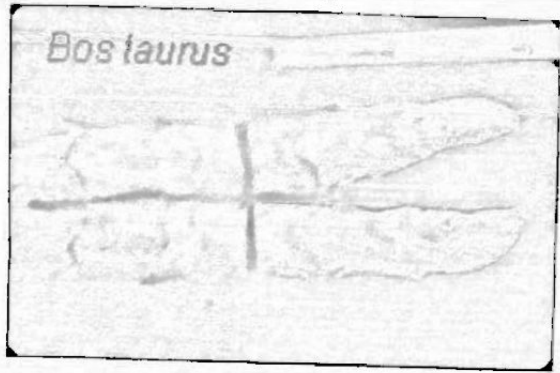



Figure: pictures of *Odocoileus virginianus* hooves that are available in the laboratory.

Figure: picture of horse hoof (*Equus caballus*) in laboratory first row, by of left is the hoof on mounted leg side view of hoof and cross-section. Bottom row in view of the cross section from the bottom



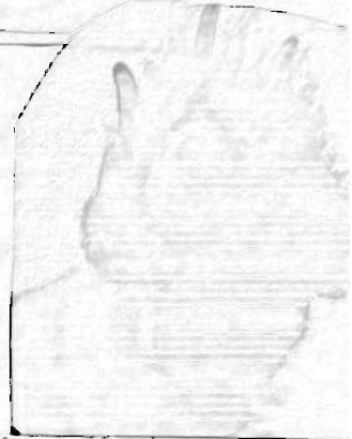Sciurus carolinensis



Condylura cristata

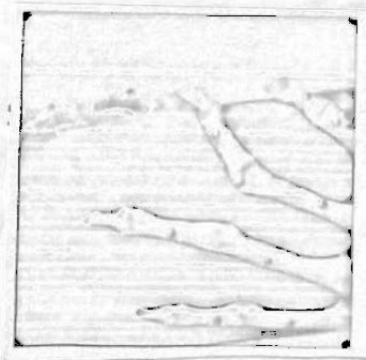



Geomys bursarius



Nails :- A nail is a simplified derivative of a claw covering only the dorsal surface of the digits. Compared to claws, the nails wide unguis is thinner and less rigid and the subunguis is very much reduced. A nail offers less protection than does a claw but expose the end of the digit to permit more precise manipulation of objects.

Figure :- Finger of human (*Homo sapiens*) and the bare skeleton of a monkey, species *Urocyon*.



safer ventral plate termed. The subunguis, the sub-
 unguis is continued by the cushion like pad. Mammals
 like cats and dogs walk on these pads. A claw is
 thicker in the median line than at the side. In add-
 ition to the protection of the tip of the digits, claws are
 used in many ways for climbing, digging, hanging or
 grasping and even killing prey

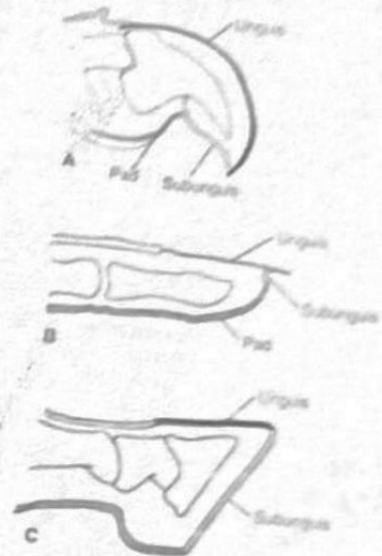
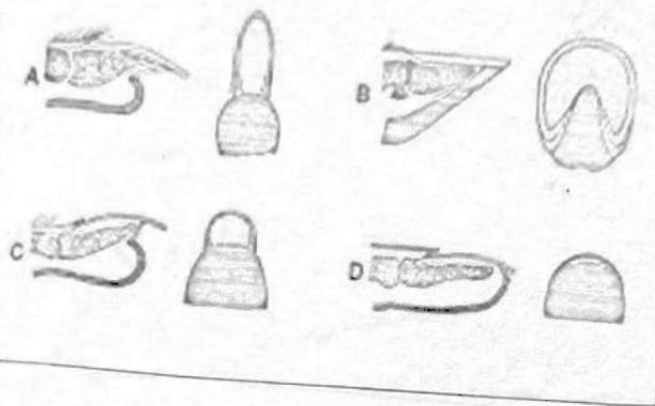


Figure 5.6 Claws, nails, and hooves. Similarities in the
 general structure but distinct variation with regard to
 specialized functions are evident for (A) claws, (B) nails and
 (C) hooves. Top views of each part are lateral sections. Unguis
 is solid black, subunguis, light grey, and pad, dark grey.

Figure :- Diagrams of claws and nails (Romer 1977
 for the horizontal figure) Feldhman 2004 for vertical
 figure).

Examine claws of an arboreal squirrel (eg: gray squir-
 rel) cat, dogs and a badger or mole. Note the unguis &
 subunguis on each

Figure: pictures of claws of several species are present
 in the lab.

(D) The pampas deer *Dicotyles* (E) the swamp-adapted marsh deer *Blastocerus* (F) the white-tailed deer *Odocoileus virginianus* tropical forests
 (G) the white-tailed deer, large meadows forests
 (H) The mule deer *Odocoileus hemionus* (I) the reindeer *Rangifer tarandus* (J) the moose *Alces alces*. The porcupine and beaver deer are ecologically "drinkers and drinkers" the beaver is a grassland; the mule deer is an swamp specialist similar to the African Sitatunga antelope; The winter-tailed, the musk and the rock deer are cold temperature zone inhabitants; the reindeer and the moose are grotesque. See Age groups with a circumpolar distribution.

Claws, Hooves, Nails

Objectives: In this section we learn about claws hooves and nails of mammals. you should be able to identify and apply correctly all underlined terms

The Ends of most digits mammals other than whales and most simians are protected by hardened plates of protein (also present in hair) These plates take the form of claws, nails or hooves. They are formed by the epidermis in a process similar to the growth of hair.

Claws:- The claw is the ancestral form of digits converging. Mammalian claws are similar to claws of reptiles and birds. A claw is composed of a harder dorsal plate called the unguitractor and a

Figure:- Sample skulls of deer (Cervidae) in the laboratory showing different aspects of antler growth.

Be able to distinguish to species the antlers of available cervids (mule deer *Odocoileus hemionus* and white-tailed deer *Odocoileus virginianus*, wapiti (elk) *Cervus Elaphus*, moose, *Alces alces*, and caribou *Rangifer tarandus*). Moose antlers are palmated, while caribou antlers have a small amount of palmation and the brow tine (on at least one of the antlers). Wapiti antlers are longer than deer-antlers and have a single beam that branches.

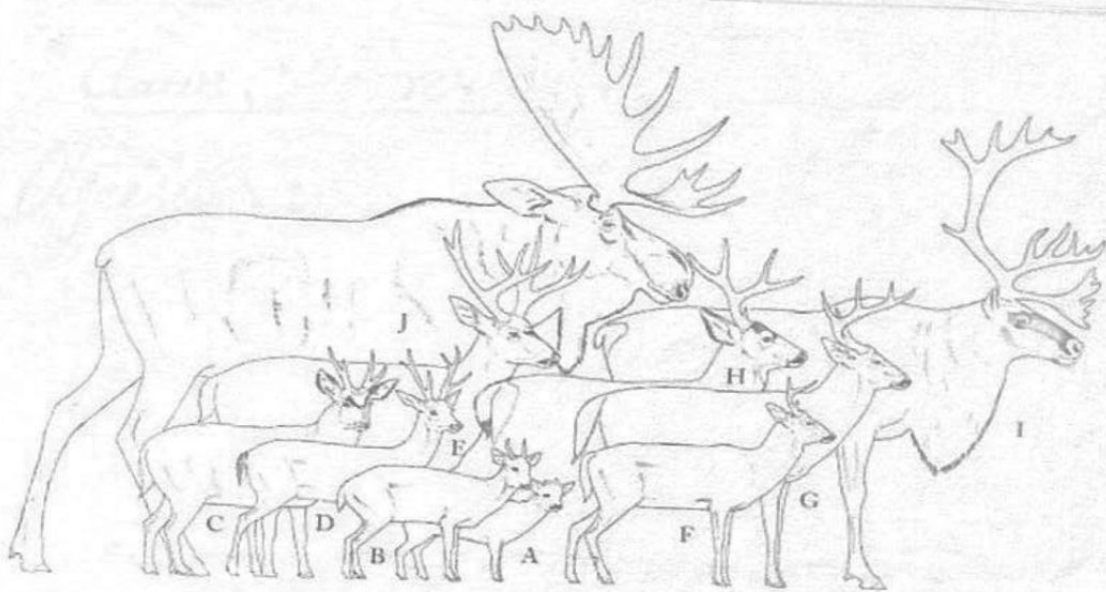


Figure:- The living new world deer, drawn to scale and arranged by size from front to rear, are very diverse in adaptation (A) The South American pudu is the smallest of all living deer (B) the brocket deer, *Mazama*; (C) the Indian mountain deer or bisonul *Hippocamelus*;

* Antlers: Antlers are only formed in the family Cervidae (Artiodactyla). Antlers are present only in males, except for female caribou (reindeer) in the genus Rangifer. Fully developed antlers are made completely of bone. The base forms bony stumps (pedicles) on the frontal bones.

The pedicles are covered with skin. The antlers themselves are shed after mating season. The developing antlers are covered with skin and hairs. Antlers are usually used only during sparring matches and in displays to potential mates and rivals. Antlers tend to use their hooves for defense when attacked by predators.

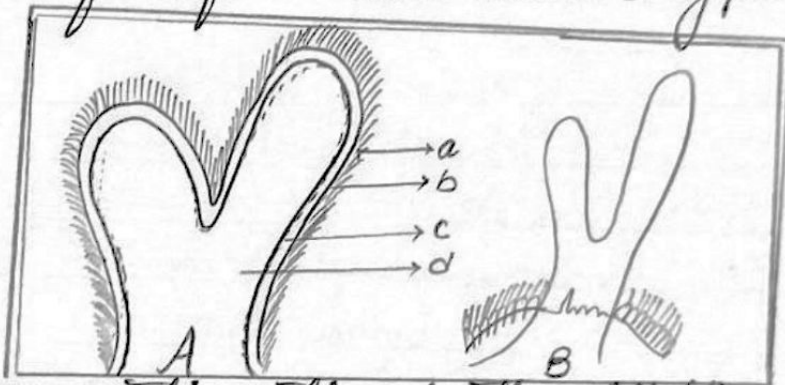
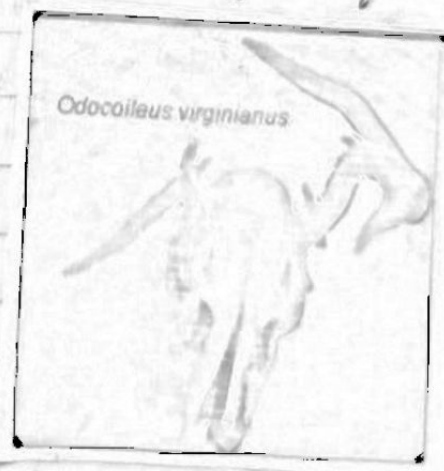
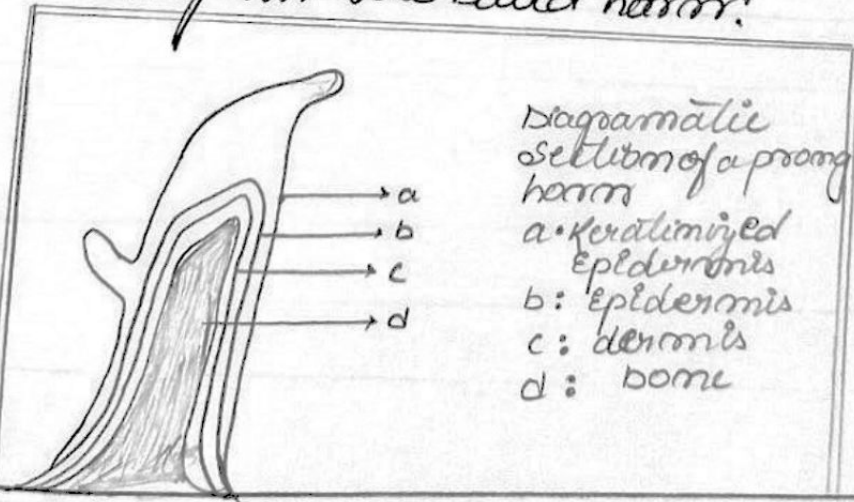


Figure: Diagrammatic section of antler with (A) and without (B) velvet: a) velvet; b) Epidermis of dermis of bone (or antler); c) abscission line at region of burr.



Examine horns and horns cores of the available bovids (Cow, Bos taurus, Oreamnos americanus) and on wall bighorn sheep, Ovis canadensis and mountain goat (Oreamnos americanus). There are no cross-sections of horns in the UMS collection. size, length and curvature of horns varies among species

Pronghorns :- The pronghorn (*Antilocapra americana*) of western north America is the only living species of the family Antilocapridae (Artiodactyla). As in the Bovidae the horn (properly called as pronghorn) has a bony core covered by a keratinized sheath and serves a similar function. However, unlike other horns, in pronghorns the sheaths are (1) branched (2) deciduous. They are shed annually after the breeding season. The new sheath grows while the old one is still in place and only pushes it off when its development is much advanced. Both old one is still but they are more prominent in males. In females sometimes the pronghorns are unbranched or absent altogether. compare the diagrams of pronghorn with the diagram the bovid horn.




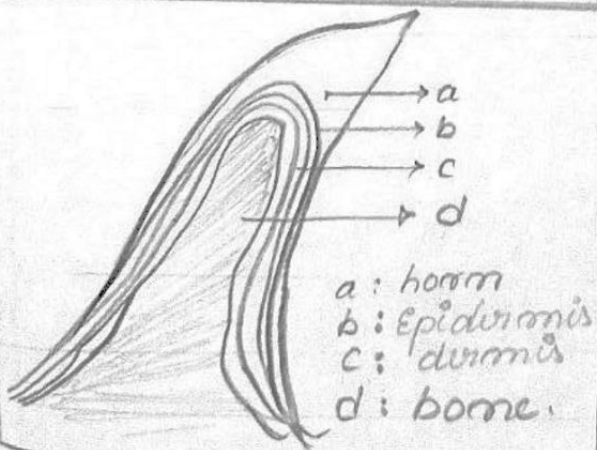
Diagrammatic
section of a prong
horn
a: keratinized
epidermis
b: epidermis
c: dermis
d: bone

Horns and Antlers

Horns and antlers are found today only in two mammalian orders, Artiodactyla and Perissodactyla. Extinct mammals from other orders (including the Rodentia) also had cranial ornaments. Their kinds can be distinguished by their location on the head and mode of development.

Horns :- True horns are found only in the family Bovidae (order Artiodactyla). True horns are always unbranched and permanent and are composed of two parts: the bony horn core and the horn itself. The horns grow from its base throughout the adult life of the animal.

Figure :- Diagram of horn (DeBlase and Maxwell 1981) on the left and the horn core and horn of a bison on the right. This specimen is available in the laboratory.





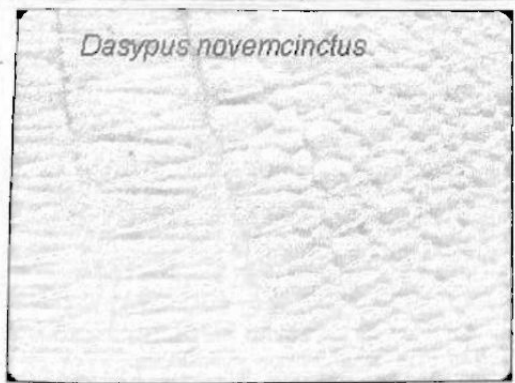


Figure:- Examine the scaly tail of beaver (*Castor canadensis*) or rat (*Rattus norvegicus*) or opossum (*Didelphis virginiana*) and note the placement of hairs in relation to the placement of scale.

The armadillo (Edentata: Dasypodidae) has both epidermal scales and dermal bone. The epidermal scales resemble the scales on the tails of the rat or beaver. The dermal bone is unique among mammals. It is true bone within the dermis, forming a shell constructed somewhat like the armor of a medieval knight.

Examine the nine-banded armadillo (*Dasypus novemcinctus*). The arrangements of dermal bone and epidermal scales.



Lepus americanus


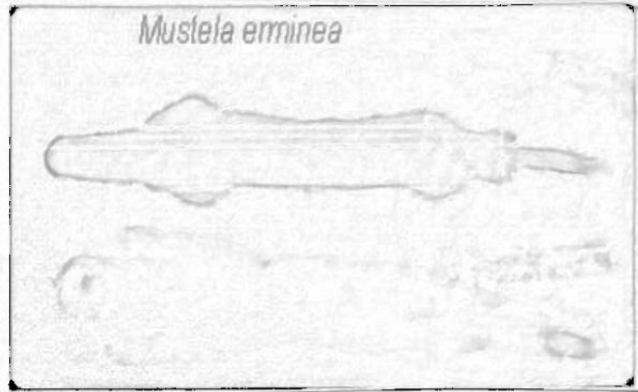


Figure: compare winter & summer pelts of the ermine (*Mustela erminea*) and snowshoe hare (*Lepus americanus*) that are present in the lab.

Mustela erminea



In many mammals there is distinctly juvenile pelage that distinguishes young animals from adult (in addition to other clues such as body size). Members of the deer family are good example of this moose claws are reddish in colour for example.

Scales: - The scales on the more or less naked tail of rats, mice and beavers are protective, epidermal thick rings of the scale made of keratinized cells. The thinner skin b/w these scales allow flexibility. The Pangolin (order pholidota) is covered with epidermal scales of a different kind. They consist of keratinized cells and are in structure and development basically equivalent to hairs. However they do not grow from follicle equivalent to hairs but from raised papillae, protruding from the surface.

<u>Order</u>	<u>Family</u>	<u>Species</u>	<u>Common name</u>
Artiodactyla	Cervidae	<u>Odocoileus hemionus</u>	Mule deer
Artiodactyla	Cervidae	<u>Rangifer tarandus</u>	Caribou
Artiodactyla	Bovidae Cervidae	<u>Bos taurus</u>	Cow
Artiodactyla	Bovidae	<u>Ovis canadensis</u>	Bighorn sheep
Artiodactyla	Cervidae	<u>Oreamnos americanus</u>	Mountain goat
Artiodactyla	Artiodactylidae	<u>Equus caballus</u>	Domestic horse
Perissodactyla	Equidae	<u>Equus caballus</u>	Horse
Rodentia	Sciuridae	<u>Sciurus carolinensis</u>	Grey squirrel
Carnivora	Mustelidae	<u>Lutra canadensis</u>	otter
Carnivora	Mustelidae	<u>Taxidea taxus</u>	Badger
Carnivora	Mustelidae	<u>Mustela erminea</u>	Ermine
Carnivora	Cervidae	<u>Alces alces</u>	Moose
Artiodactyla	Leporidae	<u>Sylvilagus floridanus</u>	Eastern cottontail
Lagomorpha	Sciuridae	<u>Lepus americanus</u>	Snowshoe hare
Rodentia	Sciuridae	<u>Marmota monax</u>	wood chuck
Xenarthra	Dasypodidae	<u>Dasyurus novemcinctus</u>	Armadillo
Rodentia	Muridae	<u>Onychomys leucogaster</u>	Mouse